

MORPHO-HISTOLOGICAL STUDY OF COCCIDIOSIS IN BROILERS IN THE SOUK AHRAS REGION, ALGERIA

Berghiche Amine^{1,2}✉, Khenenou Tarek^{1,3}✉, Boudjellel Amira¹, Grairia Amina⁴ and Labied Ibtesslem⁵

¹Institut Des Sciences Agronomiques et Vétérinaires, Université De Cherif Messaadia, Souk Ahras, Algérie.

²Laboratoire des sciences et techniques du vivant, Institut Des Sciences Agronomiques et Vétérinaires. Université De Cherif Messaadia, Souk Ahras, Algérie

³Laboratoire des Productions Animales, Biotechnologies et Santé, Institut Des Sciences Agronomiques et Vétérinaires. Université De Cherif Messaadia, Souk Ahras, Algérie

⁴Institut Des Sciences Vétérinaires, Université Ibn Khaldoun, Tiaret, Algérie

⁵Institut Des Sciences De La-Nature Et De La Vie, Université Badji Mokhtar, Annaba, Algérie

✉Supporting Information

ABSTRACT *: The aim of this study was assess the macroscopic and microscopic appearance of the normal and the abnormal gut in coccidiosis disease of broiler chickens during post hatching age in souk Ahras area. The results showed that the small intestine is the most sensitive organ to avian coccidiosis. The necropsy showed that the lesions are expressed according to the species, A strong congestion with hemorrhagic area in cecum coccidiosis. Atrophy of the intestinal villous with thickening of the mucosa was observed in the case of intestinal Coccidiosis. Microscopic translation revealed hydropic degeneration and necrosis of enterocytes with pycnotic in the intestinal mucosa and the presence of strong enteritis. Coccidiosis is one of the most frequent parasitic diseases in poultry in Algeria, it takes many forms and occurs all types of poultry farming around the world, this illness has serious economic damage, an epidemiological surveillance plan for this disease is necessary in order to control its propagation and to reduce its risk.

ORIGINAL ARTICLE
 PII: S222877011800018-8
 Received: October 02, 2018
 Revised: November 17, 2018

Keywords: Broiler Chickens, Post Hatching Age, Coccidiosis, Macroscopic and Microscopic Appearance.

INTRODUCTION

Avian coccidiosis is a very severe intestinal parasitic disease found in all parts of the world where poultry are kept, caused by protozoa of the sporozoa class: coccidia.1 (Henry et al., 1974). The coccidia of farmyard animals are mainly of the genus Eimeria (Tenter et al., 2002). Leuwenhoek discovered coccidia in 1674 when he found corpuscles in rabbit liver canals that could only be oocysts of Eimeria stiedae (Dobell, 1922).

Eimeria have a narrow specificity both for the host species and for their location along the digestive tract (Horton-Smith and Long, 1965, 1966; Long and Millard, 1976). The presence and multiplication of various coccidia of the genus Eimeria lead to the destruction of epithelial cells at the intestinal and/or caecal level during their development (Bussieras and Chermeite, 1992a); it manifests itself by an acute and fatal haemorrhagic enteritis, or by a subclinical form (Euzeby, 1987). This disease can seriously limit the development of poultry production, both in farm and industrial livestock (Yvoré et al., 1982; Sykes, 1994).

There are no farms without coccidia, but the presence of coccidia does not necessarily mean infestation (Creveieu-Gabriel and Naciri, 2001), Contamination by coccidia is an almost inevitable phenomenon in breeding. The only source of the parasite in a farm is infected animals that reject oocysts in their faeces. Contaminated by rejected oocysts, litter, feed and water also become sources of contamination (Yvoré et al., 1982; Naciri and Yvore, 1982.; Holdsworth et al., 2004). Coccidial oocysts are very resistant, especially after sporulation, which explains the durability of the infection (Matsui et al., 1989; Gajadhar et al., 2015). In water, oocysts are still infecting after 14 months (Eimeria necatrix) or even 24 months (Eimeria tenella) (Bussiéras and Chermette, 1992b).

Infection always occurs the by oral route, following ingestion of sporulated oocysts with food or drinking water. The more oocysts are ingested, the more severe the lesions. Massive ingestion at one time is more Pathogenic than the same total amount of oocysts ingested over several days. The doses required to cause disturbance vary widely between species (Conway and McKenzie, 2007; Williams, 1998). Several factors can favour the appearance or severity of coccidiosis in a farm: non-compliance with hygiene rules, overcrowding, the farming method (on slats or floors) and the management of the farm as a whole (humidity, temperature, ventilation, etc.). Responsiveness

depends on the animal species, breed, lineage, age, immune status of the animals and the existence or absence of intercurrent diseases (Bussi ras and Chermette, 1992b). Food (composition and distribution mode) also plays an important role in susceptibility to coccidiosis (Creveiu-Gabriel and Naciri, 2001; Yun et al., 2000). The frequency of coccidial infections in chickens, even under modern production conditions, reflects both the adaptability of the parasite and the way birds are raised (Yvor  et al., 1982; Chapman et al., 2002). Once a building is contaminated, it is almost impossible to completely decontaminate the environment (Carbo Baptista et al., 1976). Studies with broilers have shown that exposure to sporulated oocysts usually begins shortly after chicks are placed on the litter (Braunius and Litjens, 1984.; Sanni, 1989). Contamination by Eimeria oocysts is generally low during the first two to three weeks, increases rapidly to a peak between the fourth and sixth weeks, and then decreases around the seventh to eighth week (Conway and McKenzie, 2007; Williams, 1998).

This protozooisis is the first parasitic disease of poultry (Azeroual et al., 2013; Titilincu et al., 2007) and has a considerable economic impact on poultry farms, due to losses due to mortality and reduced performance and to the cost of medication (Shirley et al., 2007.; Kinung’hi et al., 2004; Williams, 1999; Vermeulen, et al., 2001; Lo szov  et al., 2001). The global economic cost of preventing coccidiosis (chickens and turkeys) is more than \$300 million per year (Ayad and Driss, 2015; Dalloul and Lillehoj, 2006). In medical terms, coccidiosis results in a mortality rate of up to 80-100% of the workforce (Buldgen, 1996; Triki-Yamani et al., 2014). The control of this disease is necessary for a real development of poultry farming and the timely use of prophylactic coccido-statics is a way to prevent this disease. Also poultry losses can be minimized by rapid chemotherapeutic treatment (Nweze, and Obiwulu, 2009; Hafez, 2008).

The determination of the intestinal necropsy consequences of coccidiosis in broilers is still a topic that is not studied in the pathological anatomy of poultry. Therefore, the aim of our work is a macroscopic and microscopic study of the intestine of broiler chickens in the normal state and during coccidiosis.

MATERIAL AND METHODS

Ethical approval

The experiment was carried out according to the National Regulations on Animal Welfare and Institutional Animal Ethical Committee.

Animals

The experimental study was conducted on 30 broilers 5-week-old of a single strain (coccidiosis is more susceptible in broilers between 3 and 5 weeks old), Ross strain 308 (fast-growing chicken). The animals are raised on the floor, on straw bedding in non-air-conditioned greenhouse buildings. Animals receive three types of preventive medication: an anti-infective (Vigal 2 X), an anticoccidial (Cocciديوpon), and a protective hepatoid (Renyl). During the entire breeding period, the animals received only one type of feed whose formulation is shown in Table 1, this feed originates from the ONAB (Office National des Aliments du Livestock), the feed and water for drinking have been distributed ad libitum.

Table 1 - The composition of the food (ONAB).

Food	Quantities (%)
Corn	64.8%
Soja	27%
C.M.V (mineralo-vitamin supplement)	1%
Calcareous	1.2%
Gros son	5%
Phosphate	1%

Instrumentations

For the realization of this work the following equipment was used:

- Auto-clave memmert model 100-800
- SLEE MAINZ PLC / Type MTP / SN : K12024
- Paraffin / Nahita dispenser. Model No. 520
- OPTIKA photonic microscope
- DM series photographic microscope. OPTICA
- Microtome SLEE / CUT4062 / SN : A120038
- Cooling plate / Nahita. Model No. 520/1
- Dissection Kit

Methods

Macroscopic study of the intestine in the normal state and during coccidiosis disease. Necropsies are performed on freshly euthanized chickens to maintain the integrity of the organs and tissues to be examined. The animals are sacrificed in the gentlest possible way, quickly dissected, the intestines carefully removed to avoid the risk of crushing and then placed in vials filled with fixative (10% formaldehyde).

Macroscopic study: Observation of the intestine with the naked eye, in both normal and abnormal states (in coccidiosis disease)

The microscopic study

Fixation of the organs. There are several fixing agents but formaldehyde remains the best fixative because it can fix large parts without dissection and penetrates quickly into the tissues.

Post fixation. Remove the attached intestine and put them under tap water for at least three hours, then cut three to six fragments and place them in identified plastic cassettes. According to Luna (1968), we have the following successive passages: Ethanol 80% (4 hours), Ethanol 95% (2 hours), 100% ethanol (3 hours), Xylene (2 hour), Paraffin (13 hours). The purpose of this passage in the automaton is dehydration (passages in alcohols, of different degrees); thinning (xylene) and impregnation (infiltration) in the paraffin. The duration of the passage of the fragments through the PLC is 24 hours.

Blocking. The paraffin inclusion is carried out within a device set at 55°; the parts are placed in stainless steel moulds then the heated paraffin is poured into the moulds and puts the labels on top of the molds; then the molds are detached after a complete cooling. The parts are put in blocks and kept cold indefinitely.

Microtomization and gluing of the cuts on the blade. They make it possible to obtain cuts whose thickness is from 5 to 7µ and to put them on a transparent glass support. The procedure described by Darboux (1994) should be followed, which includes the following steps:

Rendering by the removal of excess paraffin with a knife. Mounting the block on its support; the block must remain parallel to the knife. The microtome roughing eliminates the paraffin in front of the sample to obtain a complete cut of the tissue to be stained. The actual cutting is obtained by regularly passing the part to be cut in front of the razor or knife of the microtome. The glueing of the cups on a glass slide; on each slide is engraved the identification number of the block. The cutting is done on a heated plate and the drop of gelatinous water placed on the blade holds the cut on the blade.

Drying of the blades. It is made in an oven at 60°C for 24 hours, the cups are then covered with a thin film of paraffin which protects them from the air and keeps them indefinitely.

Staining with Eosin Haematoxylin:

- Xylene (4 minutes).
- 100% ethanol (2 minute).
- Ethanol 95% (1 minute).
- Tap water (10 minutes)
- Hematoxylin (15 minutes).
- Tap water (washing).
- Alcohol Acid: 3 to 5 dips.
- Tap water briefly.
- Ammoniacal water (ammonia waters): 3 to 5dips.
- Tap water (10 to 20 minutes).
- Eosin (15 seconds to 2 minutes).
- Ethanol 95% (2 minutes).
- 100% ethanol (4 minutes).
- Xylene (4 minutes).

Taking pictures. It is done through the use of a camera integrated in the DM series optical photographic microscope (OPTIKA); the sensitivity of this camera is adjusted to the sensitivity of the film used (100 ASA).

RESULTS

Results of macroscopic and histological study of the intestine in its normal state and during coccidiosis have been presented in the following figures (Figures 1-2 for normal state, and Figures 3-6 for during coccidiosis).

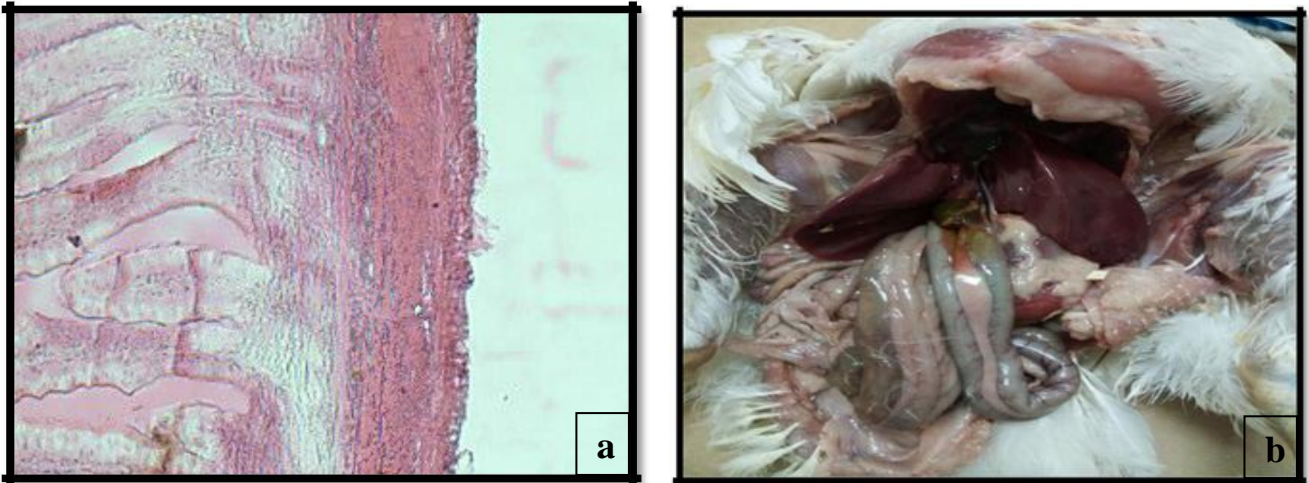


Figure 1 - (a) Intestine of a broiler chicken; **(b)** Intestine in a 5-week old broiler chicken (H&Ex40).

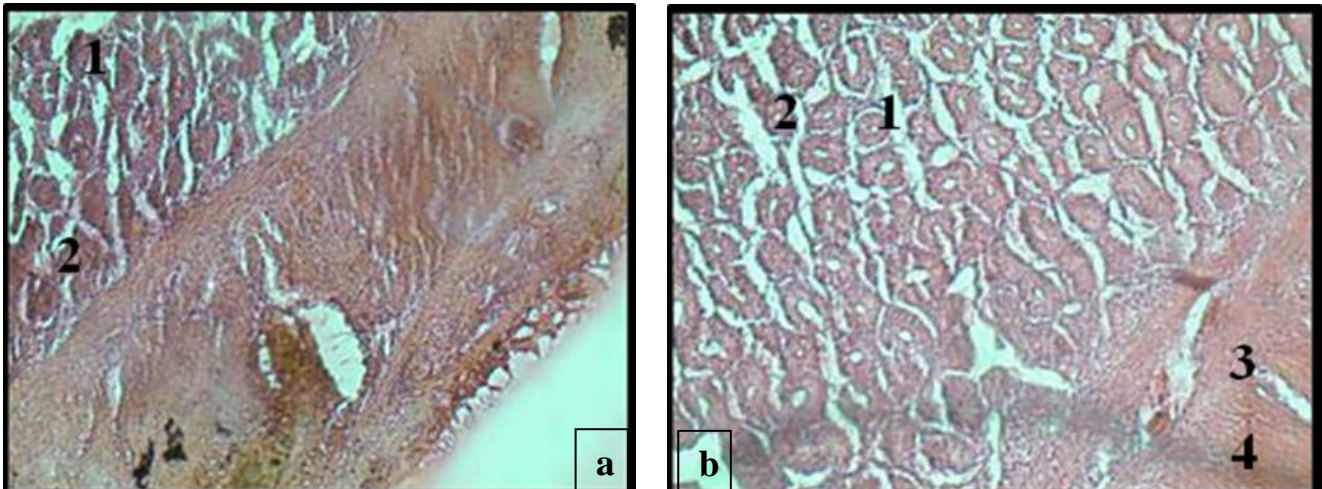


Figure 2 - (a) Intestine in a 5-week old broiler chicken (H&Ex100) 1: enterocytes. 2: villosity, **(b)**Intestin in a 5-week old broiler chicken (H&Ex100) 1: enterocytes; 2: villosity; 3: mucous membrane; 4: muscular membrane.

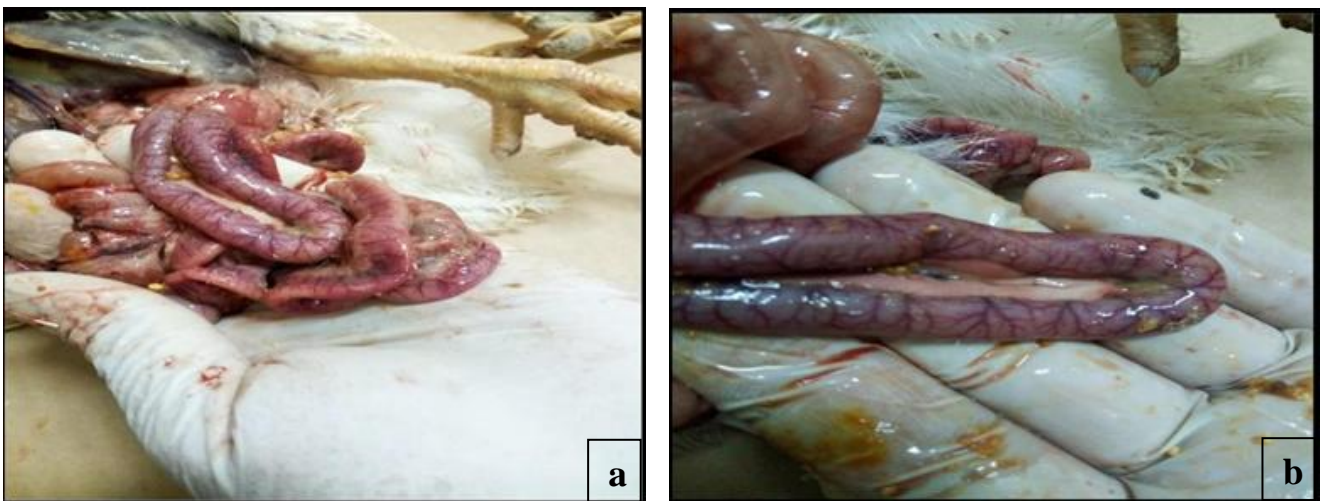


Figure 3 - (a) The presence of severe congestion in the duodenal area during the acute phase of *coccidiosis* **(b)** Congestion of the jejunal part during the acute phase of *coccidiosis*.

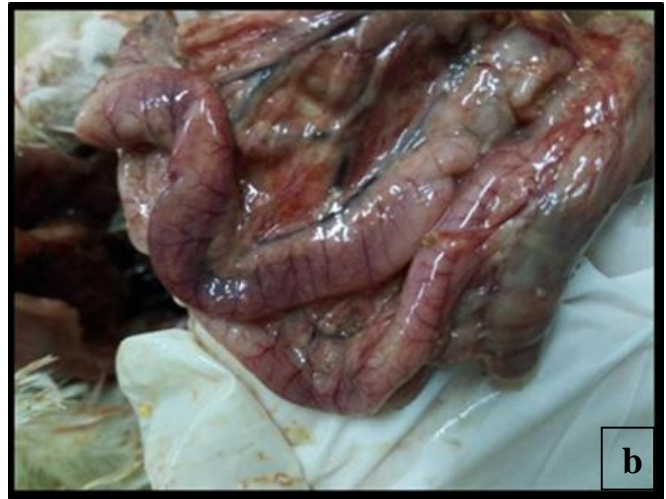
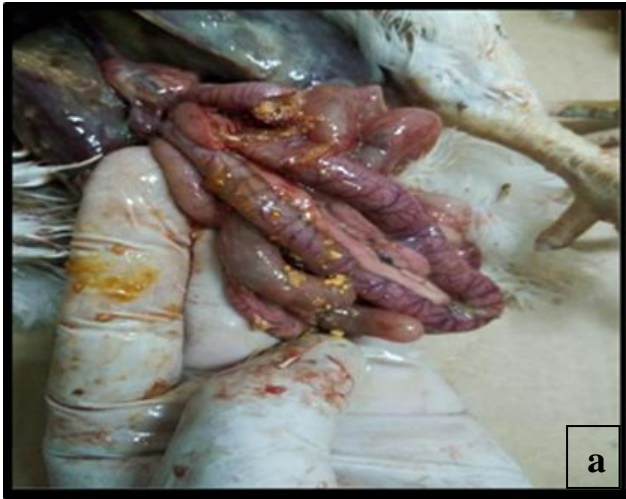
Figure 4 - (a) Congestion of the jejunal part during the acute phase of coccidiosis (b) The presence of congestion during caecal Coccidiosis

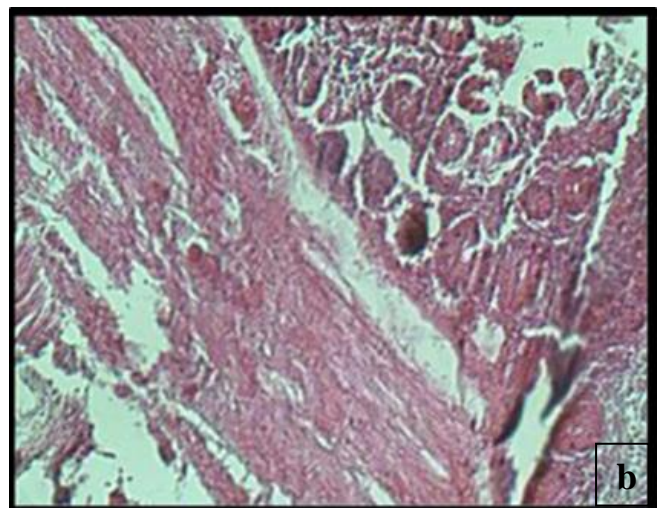
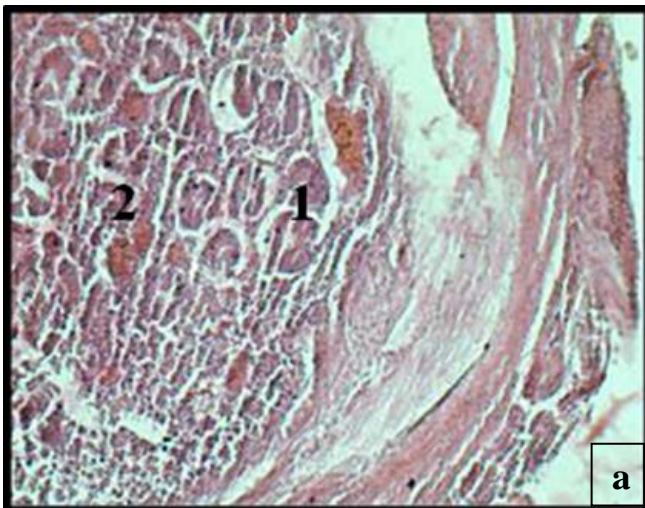


Figure 5 - (a) Histological aspect of intestinal coccidiosis with a degenerative phase of enterocytes. 1: oocyst. 2: degeneration. (b) Enteritis caused by coccidiosis (H&Ex100).

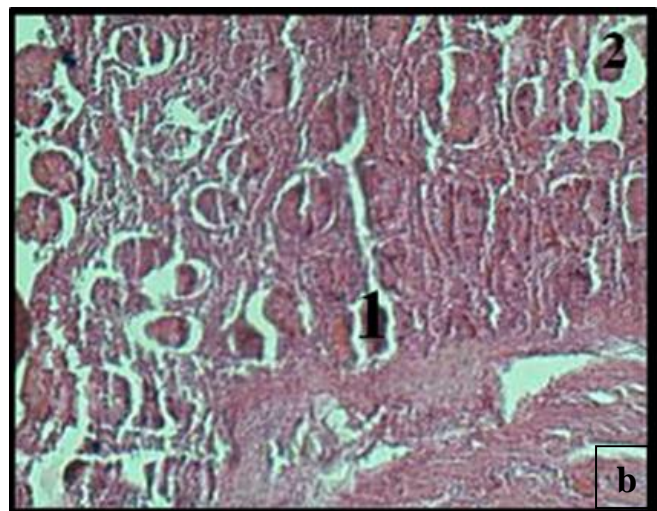
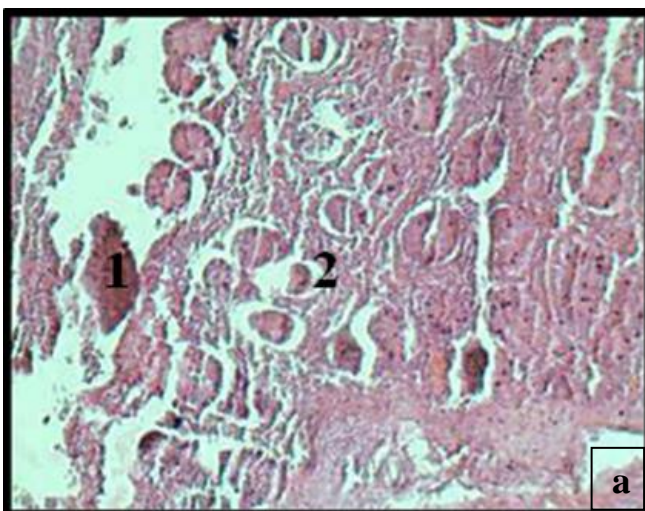


Figure 6 - (a) Intestinal coccidiosis with enterocyte necrosis and pycnosis (H&Ex100); 1: necrosis. 2: pycnosis (b) The presence of significant acute intestinal inflammation with hydrophilic degeneration during intestinal coccidiosis; 1: degeneration. 2: oocyst.

REFERENCES

- Akakpo MJA (1974). Ghislain ELLA ABOGHE (Doctoral dissertation, UNIVERSITE CHEIKH ANTA DIOP DE DAKAR)
- Ayad A and Driss N (2015). Prévalence et étiologie de la coccidiose dans les élevages de poulet de chair (Bejaia).
- Azeroual E, Mesfioui A, Oukessou M, Bouzoubaa K, Benazzouz B and Ouichou A (2013). Effet Coccidiostatique de Neuf Plantes Aromatiques et Médicinales Incorporées Comme Additifs Alimentaires Dans le Régime Des Poules Pondeuses. *European Journal of Scientific Research*, 99 (2): 200-207.
- Boireau P, Guillot J, Polack B, Vallee I and Chermette R (2002). Risques parasitaires liés aux aliments d'origine animale. *Revue Française des Laboratoires*, 348 : 71-89.
- Bouhelier B (2005). Prévalence des coccidies en élevage de poulets sous Label Rouge du Gers. Etude expérimentale (Doctoral dissertation).
- Braunius W W and Litjens J B (1984). Coccidiosis during the rearing of broiler breeding stock in Limburg. *Tijdschrift voor diergeneeskunde*, 109(10), 394-401.
- Brugère-Picoux J and Silim A. (1992). Manuel de pathologie aviaire. Ed. Chaire de Pathologie Médicale du Bétail et des Animaux de Basse-Cour, Ecole Nationale Vétérinaire d'Alfort.
- Buldgen A (1996). Small-scale poultry farming in the subtropics: a practical guide. *Small-scale poultry farming in the subtropics: a practical guide*.
- Bussieras J and CHERMETTE R (1992a). Fascicule II: Protozoologie vétérinaire. Abrégé de parasitologie vétérinaire. Edition: Alfort.
- Bussieras J and Chermette R (1992b). Abrégé de Parasitologie vétérinaire: Fascicule II: Protozoologie vétérinaire. Maison Alfort: ENValfort, Edité par le service de parasitologie-p
- Carbo'baptista N, Larbier M and Yvore P (1976). Influence de la coccidiose duodénale à *Eimeria acervulina* sur l'absorption intestinale de la lysine et sur les mouvements nets de l'eau et des électrolytes. *Avian Pathology*, 5(3), 187-194.
- Chapman HD, Jeffers TK and Williams RB (2010). Forty years of monensin for the control of coccidiosis in poultry. *Poultry Science*, 89(9), 1788-1801.
- Chapman HD (2014). Milestones in avian coccidiosis research: a review. *Poultry science*, 93(3): 501-511.
- Chapman H, Cherry T E, Danforth HD, Richards G, Shirley MW and Williams RB (2002). Sustainable coccidiosis control in poultry production: the role of live vaccines. *International Journal for Parasitology*, 32(5), 617-629
- chene-vert SÉG and Curie RM (2008). Rencontres interprofessionnelles de pathologie aviaire.
- Cheraft S, Kandi S and Ayad AE (2017). Effet d'extrait de *Fumaria capreolata* sur les oocystes *Eimeria* chez le poulet de chair.
- Conway DP and Mckenzie ME (2007). *Poultry coccidiosis: diagnostic and testing procedures*. John Wiley & Sons.
- Creveu-Gabriel I and Naciri M (2001). Effet de l'alimentation sur les coccidioses chez le poulet. *Productions Animales* 4 (14), 231-246.
- Dalloul RA and Lillehoj HS (2006). Poultry coccidiosis: recent advancements in control measures and vaccine development. *Expert review of vaccines*, 5(1): 143-163.
- Dobell C (1922). The discovery of the coccidia. *Parasitology*, 14(3-4): 342-348.
- Gajadhar A A, Lalonde L F, Al-adhami B, Singh B B and Lobanov V (2015). Foodborne apicomplexan protozoa: Coccidia. In *Foodborne Parasites in the Food Supply Web* (pp. 101-147).
- Hafez H M (2008). Poultry coccidiosis: Prevention and control approaches. *Archiv Fur Geflugelkunde*, 72(1), 2-7.
- Henry K, Bird R G and Doe W F (1974). Intestinal coccidiosis in a patient with alpha-chain disease. *Br Med J*, 1(5907), 542-543.
- Holdsworth P A, Conway D P, Mckenzie M E, Dayton A D, Chapman H D, Mathis G F, ... and Williams R B (2004). World Association for the Advancement of Veterinary Parasitology (WAAVP) guidelines for evaluating the efficacy of anticoccidial drugs in chickens and turkeys. *Veterinary Parasitology*, 121(3-4), 189-212.
- horton-smith C, Long P L and Pierce A E (1963). Behavior of invasive stages of *Eimeria tenella* in the immune fowl (*Gallus domesticus*). *Experimental parasitology*, 14(1), 66-74.
- Horton-smith C and Long P L (1963). Coccidia and coccidiosis in the domestic fowl and turkey. In *Advances in parasitology* (Vol. 1, pp. 67-107). Academic Press.
- Kassai T, Del campillo MC, Euzeby J, Gaafar S, Hiepe T and Himonas CA (1988). Standardized nomenclature of animal parasitic diseases (SNOAPAD). *Veterinary Parasitology*, 29(4), 299-326.
- Kinung'hi SM, Tilahun G, Hafez HM, Woldemeskell M, Kyule M, Grainer M and Baumann MP (2004). Assessment of economic impact caused by poultry coccidiosis in small and large scale poultry farms in Debre Zeit, Ethiopia. *International Journal of Poultry Science*, 3(11), 715-718.
- Long PL and Horton-smith C (1968). Coccidia and coccidiosis in the domestic fowl. In *Advances in parasitology*, 6, 313-325. Academic Press.
- Loósová A, Revajová V, LEvkut M And Pist J (2001). Pathogenesis of *Eimeria colchici* in the Intestine of Chickens and their Immune Response. *Acta Veterinaria Brno*, 70(2), 191-196.
- Matsui T, Fujino T, Kobayashi F, Tsutsumi Y and Tsuji M (1996). Attenuation of *Eimeria caviae* by selection for precocious development. *International journal for parasitology*, 26(11), 1243-1248.
- Messai A (2015). Utilisation de l'armoise et de l'eau de riz en traitement adjuvant de la coccidiose chez le poulet de chair.
- Molla B and Ali A (2015). Epidemiological study on poultry coccidiosis: Prevalence, species identification and post mortem lesions in grower chicken in Kombolcha, North-Eastern Ethiopia. *Journal of Veterinary Medicine and Animal Health*,

7(1), 1-8.

- Naciri M and Yvone P (1982). Developpement d'Eimeria tenella, agent d'une coccidiose caecale du poulet, chez un hôte non spécifique: existence d'une forme exointestinale infectante. Comptes rendus des séances de l'Académie des sciences. Série III: Sciences de la vie. 155-172.
- Ndiaye M P D, Pangui M L J, Assane M M, Kaboret M Y Y and Bonfoh M B (1964). Waké Kissao rCHEDRE (Doctoral dissertation, UNIVERSITE CHEIKH ANTA DIOP DE DAKAR).
- Nweze N E and Obiwulu I S (2009). Anticoccidial effects of Ageratum conyzoides. Journal of Ethnopharmacology, 122(1), 6-9.
- Reid W M and Johnson J (1970). Pathogenicity of Eimeria acervulina in light and heavy coccidial infections. Avian diseases, 166-171.
- Sanni J Y (1989). Docteur En Médecine Vétérinaire (DIPLOME D'ÉTAT) (Doctoral dissertation, UNIVERSITE CHEIKH ANTA DIOP DE DAKAR).
- Shirley M W, Smith A L and Blake D P (2007). Challenges in the successful control of the avian coccidia. Vaccine, 25(30), 5540-5547.
- Sykes A R (1994). Parasitism and production in farm animals. Animal Science, 59(2), Williams, R. B. (1998). Epidemiological aspects of the use of live anticoccidial vaccines for chickens. International journal for parasitology, 28(7), 1089-1098.
- Tenter A M, Heckeroth A R and Weiss L M (2000). Toxoplasma gondii: from animals to humans. International journal for parasitology, 30(12-13), 1217-1258.
- Titilincu A, Cozma V And Lefkaditis M (2007). Passive immunity in poultry Eimeriosis. Scientia Parasitologica, 1, 80-90.
- triki-yamani R R, Said R M, Benaissa F, Bachir-pacha M and Bouyoucef A (2014). The coccidiosis of the broiler in the sub-Saharan regions (Biskra-Algeria). Bulletin of University of Agricultural Sciences and Veterinary Medicine Cluj-Napoca. Veterinary Medicine, 71(1), 237-241.
- Vermeulen A N, Schaap D C and Schettters T P (2001). Control of coccidiosis in chickens by vaccination. Veterinary Parasitology, 100(1-2), 13-20.
- Williams R B (1999). A compartmentalised model for the estimation of the cost of coccidiosis to the world's chicken production industry. International journal for parasitology, 29(8), 1209-1229.
- Yun C H, Lillehoj H S and Lillehoj E P (2000). Intestinal immune responses to coccidiosis. Developmental & Comparative Immunology, 24(2-3), 303-324
- Yvone P (1992). Les coccidioses en aviculture. Manuel de Pathologie aviaire. J. Brugère-Picoux and A. e. Silim, eds. Ecole Nationale Vétérinaire d'Alfort, Maison-Alfort, France, 312-317.
- Yvone P, Naciri M, Lafont J P and Renault L (1982). Les coccidioses-aspects étiologiques et pathologiques. Le Point Vétérinaire, 14(66), 23-29.

ÉTUDE MORPHO-HISTOLOGIQUE DE LA COCCIDIOSE CHEZ LES POULETS DE CHAIR DANS LA RÉGION DE SOUK AHRAS, ALGÉRIE

Berghiche Amine^{1,2}, Khenenou Tarek^{1,3}, Boudjellel Amira¹, Grairia Amina⁴ and Labied Ibtesssem⁵

¹Institut Des Sciences Agronomiques et Vétérinaires, Université De Cherif Messaadia, Souk Ahras, Algérie.

²Laboratoire des sciences et techniques du vivant, Institut Des Sciences Agronomiques et Vétérinaires. Université De Cherif Messaadia, Souk Ahras, Algérie

³Laboratoire des Productions Animales, Biotechnologies et Santé, Institut Des Sciences Agronomiques et Vétérinaires. Université De Cherif Messaadia, Souk Ahras, Algérie

⁴Institut Des Sciences Vétérinaires, Université Ibn Khaldoun, Tiaret, Algérie

⁵Institut Des Sciences De La-Nature Et De La Vie, Université Badji Mokhtar, Annaba, Algérie

RESUME: *L'objectif de notre travail est d'étudier l'aspect macroscopique et microscopique de l'intestin à l'état normal et lors de la coccidiose chez le poulet de chair pendant la vie postnatale à la région de souk Ahras. Les résultats montrent que l'intestin grêle est l'organe le plus sensible à la coccidiose aviaire, l'examen nécropsique montre que les lésions sont exprimées selon l'espèce. Une forte congestion avec des zones hémorragiques dans le cas de la coccidiose caecale, la traduction macroscopique montre une atrophie des villosités intestinales avec un épaissement de la muqueuse dans le cas de la coccidiose intestinale, l'examen histologique révèle une dégénérescence parfois hydropique et nécrose des entérocytes avec pycnose au niveau des cellules de l'épithélium intestinal et la présence d'une forte entérite. La coccidiose est l'une des maladies parasitaires les plus fréquentes chez les volailles en Algérie, elle prend de nombreuses formes et touche tous les types d'aviculture dans le monde, cette pathologie a de graves dommages économiques, un plan de surveillance épidémiologique de cette affection est nécessaire afin de contrôler sa propagation et de réduire son risque.*

Mots clés: Poule De Chair, Intestin, Coccidiose, Aspect Macroscopique Et Microscopique.